

Ayurvedic and Modern Approach to Cleft Lip w.s.r. to *Austha sandhan*

Gunjan Keshri^{1*}, Subhash Y. Raut², Arun M. Lakhapati³ and Nita M. Kedar⁴

^{1,2,3,4}Shalyatantra Department, Government Ayurvedic Hospital, Sakkardara square, Nagpur, Maharashtra, India

Abstract

Plastic or reconstructive surgery in Ayurveda comes under the heading of Sandhan karma. Acharya Sushruta have mentioned Sandhan karma for various types of deformities of *Nasa*, *Karna* and *Austha* in *Karnavyadhabandhvidhiadhyay*.

Cleft lip and cleft palate are congenital abnormalities of the mouth and lip. Acharya Sushruta have already described it as birth abnormality in his text. Cleft lip is an abnormality in which the lip does not completely form during fetal development. Cleft palate occurs when the roof of the mouth does not completely close, leaving an opening that can extend into the nasal cavity.

This study shows the evolution of modern surgery of cleft lip from Ayurvedic cosmetic surgery of *Austha sandhan* and highlights the principles of Sandhan karma.

Keywords

Cleft lip, Cleft palate, Austha sandhan



Greentree Group

Received 04/06/16 **Accepted** 30/06/16 **Published** 10/07/16

INTRODUCTION

Acharya Sushruta, the father of Indian surgery has mentioned cosmetic surgery by

describing *Karna*, *Nasa* and *Aushtha sandhan* in *Karnavyadhabandhvidhiadhyay*¹. Acharya Vagbhata also mentioned cleft lip as *khandaushta* due to vata prakopa and described its management as sandhan karma².

Cleft lip and Cleft palate

Cleft lip and cleft palate are birth abnormalities of the mouth and lip. Acharya Sushruta and Acharya Vagbhata have already described it as birth abnormality in his text. Cleft lip and cleft palate occur early in pregnancy when the sides of the lip and the roof of the mouth do not fuse together as they should. A child can have cleft lip, cleft palate, or both. Cleft lip and cleft palate together are more common in boys.

Cleft palate

Cleft palate occurs when the roof of the mouth does not completely close, leaving an

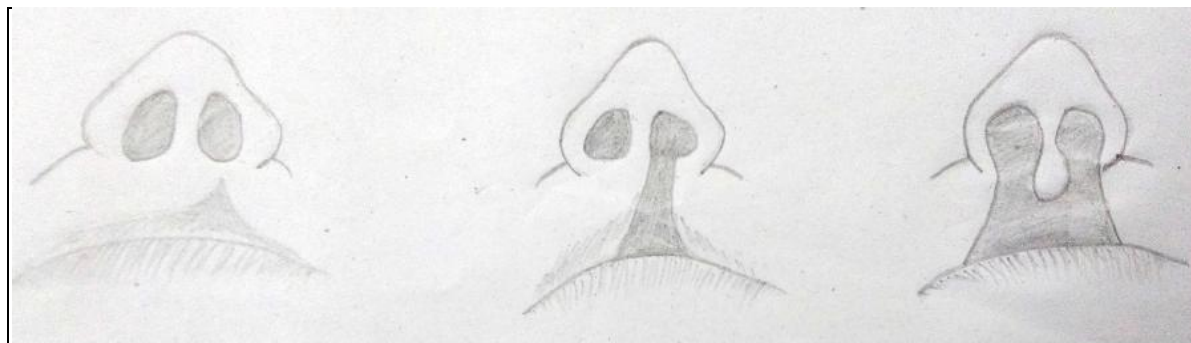
opening that can extend into the nasal cavity. The cleft may involve either side of the palate. It can extend from the front of the mouth (hard palate) to the throat (soft palate).

Cleft lip

Cleft lip is an abnormality in which the lip does not completely form during fetal development. The degree of the cleft lip can vary greatly, from mild (notching of the lip) to severe (large opening from the lip up through the nose).

There are different names given to the cleft lip according to its location and how much of the lip is involved.

Cleft lip and cleft palate may occur together in an infant, or separately.



Unilateral incomplete

unilateral complete

bilateral complete

Fig. 1 Classification of cleft lip

Unilateral incomplete- disruption of soft tissue to variable extent

Unilateral complete – complete disruption
Bilateral complete- both sides are involved

Causes of cleft lip and cleft palate

The exact cause of cleft lip and cleft palate is not known. Cleft lip and/or cleft palate are caused by multiple genes inherited from both parents, as well as environmental factors.

It can be considered as Kulaja / Sahaja / Kulodbhav / Prakritiprabhav Vyadhi according to ayurvedic Acharyas.

Symptoms of cleft lip and cleft palate

The symptoms of these abnormalities are visible during the first examination.

Possible complications associated with cleft lip and cleft palate:

- **Cosmetic abnormality**
- **Feeding difficulties**
- **Ear infections and hearing loss**
- **Speech and language delay**
- **Dental problems**

Management

Procedure for Austha sandhan

Acharya Sushruta described sandhan of congenital deformity of lip same as Nasa sandhan. The only difference is that in lip surgery there is no use of stem of Ricinus

communis (Eranda naala)¹. He told to do Lekhan karma on Lip edges and create fresh bleeding and then suturing done. Lalchandana, mulethi, rasaunt powder was then sprayed, covered with cotton and til taila was spread over that continuously. Ghritapan was then advised after digestion followed by virechana karma¹.

Acharya Vagbhata mentioned, Khandaustha chikitsa as followed – first snehan-swedana then sanshodhana and lekhana karma over lip edges followed by suturing. Sadyovrana and vata nashak chikitsa is advised afterwards².

Surgery indicated in modern seems to be originated from ayurvedic surgery mentioned by Acharya Sushruta.

Lekhan karma which is done in Ayurveda can be compared to the flaps removed from lip. Main purpose of this step is just to create fresh bleeding which is required for healing. Suturing and then dressing was then advised by Acharya Sushruta and in modern surgery also.

Tennison- Randall procedure

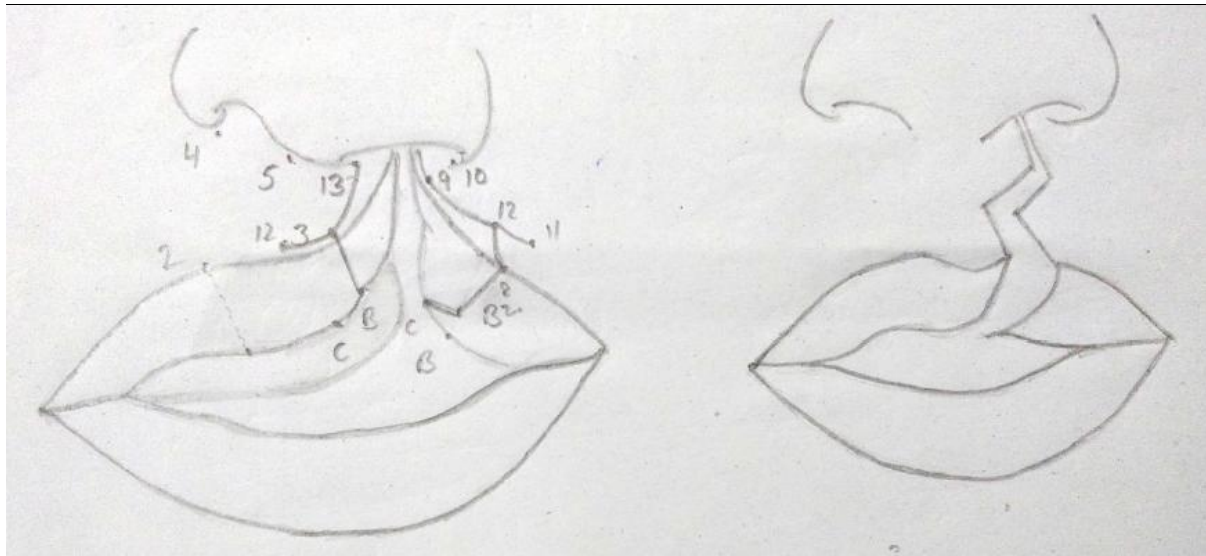


Fig 2 Tennison-Randall procedure

Cleft lip repair done generally at 3 months. Rule of tens employed in cleft lip surgery related to increased anaesthetic safety in infants

- Baby 10 week old
- Weight 10 pound
- Hb 10 mg/dl

This operation is totally based upon mathematical principles and measurements. Different landmarks are firstly made with the help of wooden stick and methylene blue dye. Then incision taken along the lines marked in the figure and suturing done as showed in second figure.

Post operative care

Acharya Sushruta mentioned Avchurnan of different herbal drugs and til taila Sinchan as

a post operative care and Acharya Vagbhata advised Sadyovrana and Vata nashak chikitsa to promote wound healing.

According to modern science,

- a) Arm restraints for 3 weeks to prevent disruption of repair.
- b) Specialized nipple/bottle to decrease sucking effort.
- c) Soft diet should be given to the child for 7 to 10 days after surgery.

Complications of cleft lip repair

- 1) Inadequate reapproximation.
- 2) Inaccurate alignment of the vermilion cutaneous junction leaving step off deformity.
- 3) Vertical scar contracture or inadequate rotation can cause shortening of the lip segment leading to a notch in the vermilion and a whistle deformity.

- 4) Narrow nostril with vestibular stenosis.
- 5) Dehiscence and scar widening.

CONCLUSION

After reviewing literature of Ayurveda and modern science it is observed that, the keen knowledge of Acharya Sushruta while mentioning the Sandhan karma as a management of Karna, Nasa, and Austha. Which denotes that modern surgical techniques like plastic surgery is derived from the basic principles of Ayurveda stated by Acharya Sushruta as a Sandhan karma in his ancient text, Sushruta samhita.

REFERENCES

1. Ambika dutt shastri(2010). Ayurvedtatvasandipika on Sushruta samhita. 84-91
2. Brahmanand tripathi(2013). Astanghridyam. 1022,1035
3. Bart van de ven(2008). Cleft lip surgery a practical guide 12-66
4. Shriram Bhatt M(2009).SRB's Manual of Surgery, 301-304
5. Makhan Lal Shah(2013). Bedside Clinics in Surgery, 478-487
6. Bailey and Love(2004). Short Practise of Surgery, 645-649
7. Margaret Farrquharson and bredan moran. 9th Edition. Farquharson's Textbook of Operative General Surgery, 186-188